



SINDROME DI ALCAPA

Sindrome Bland-White-Garland

AOU MEYER

U.O. Anestesia - Rianimazione Pediatrica
ed Endoscopia Respiratoria
Primario dott. L.Mirabile



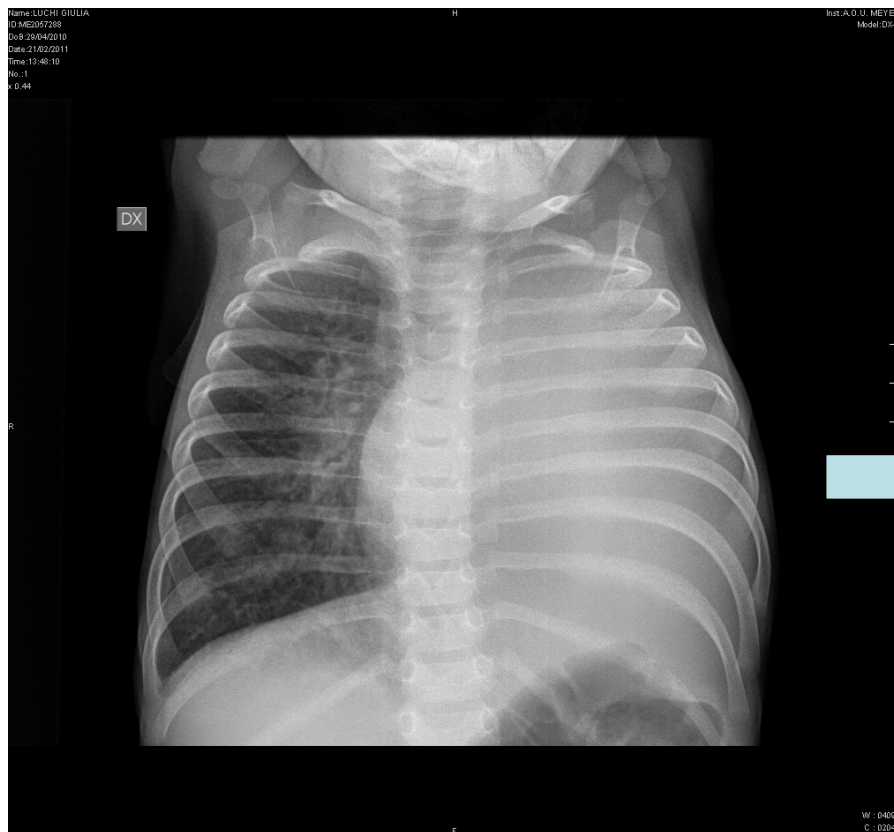
L.G. nata a termine da parto naturale il 19/04/2010.

La bambina ha presentato scarso accrescimento e infezioni respiratorie ricorrenti.



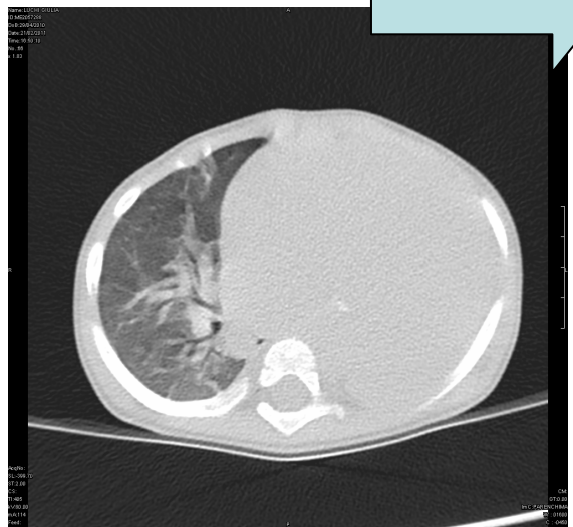
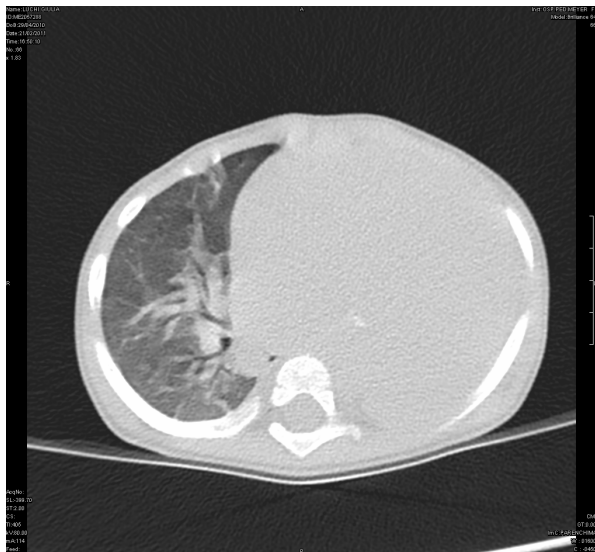
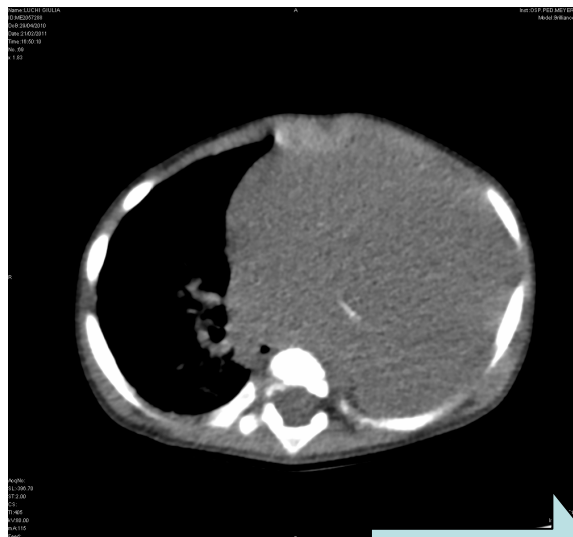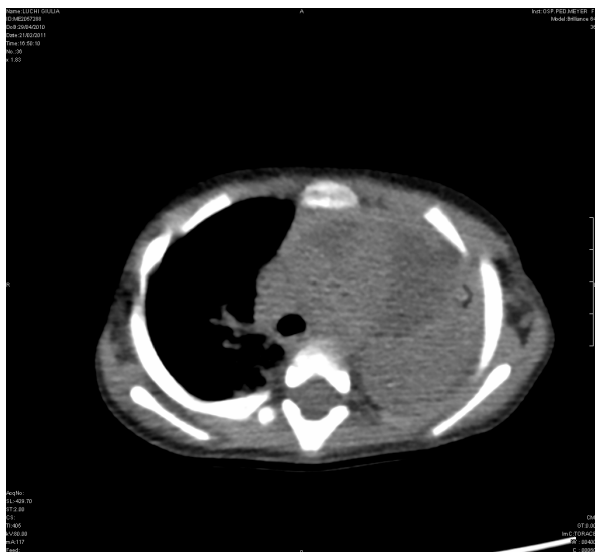21/02/2011

ricovero in Pediatria AOU Meyer



Massa mediastinica





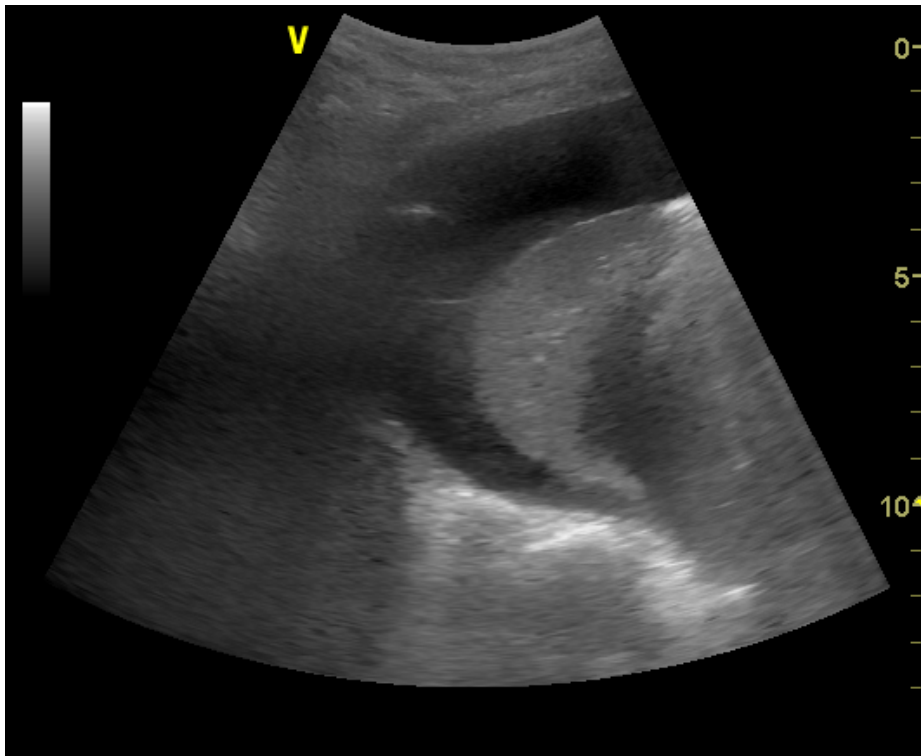
ATELETTASIA POLMONE Sn
CARDIOMEGALIA

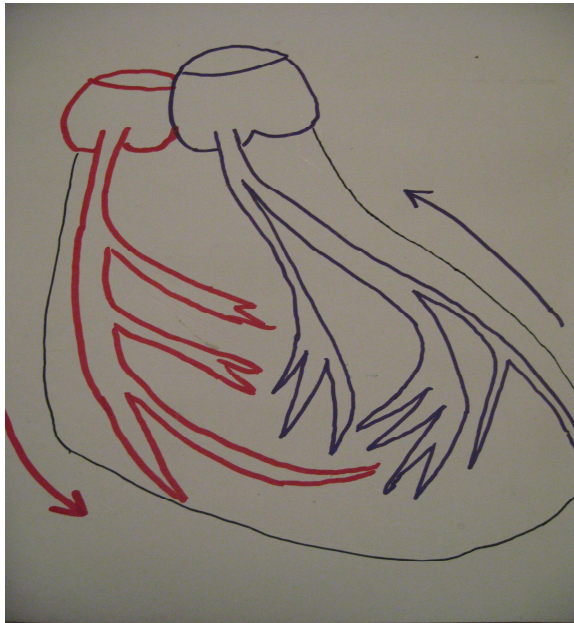


ECOCARDIOGRAMMA:

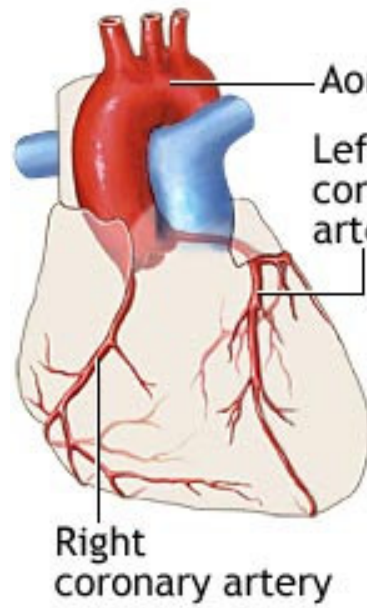
DIAGNOSI S. DI ALPACA

origine anomala coronaria destra da tronco polmonare

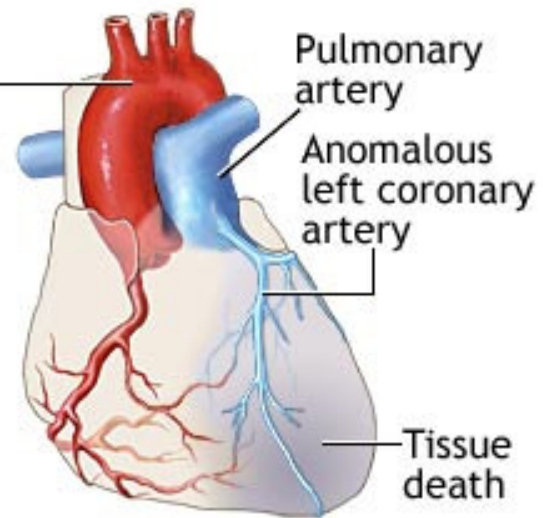




Normal heart



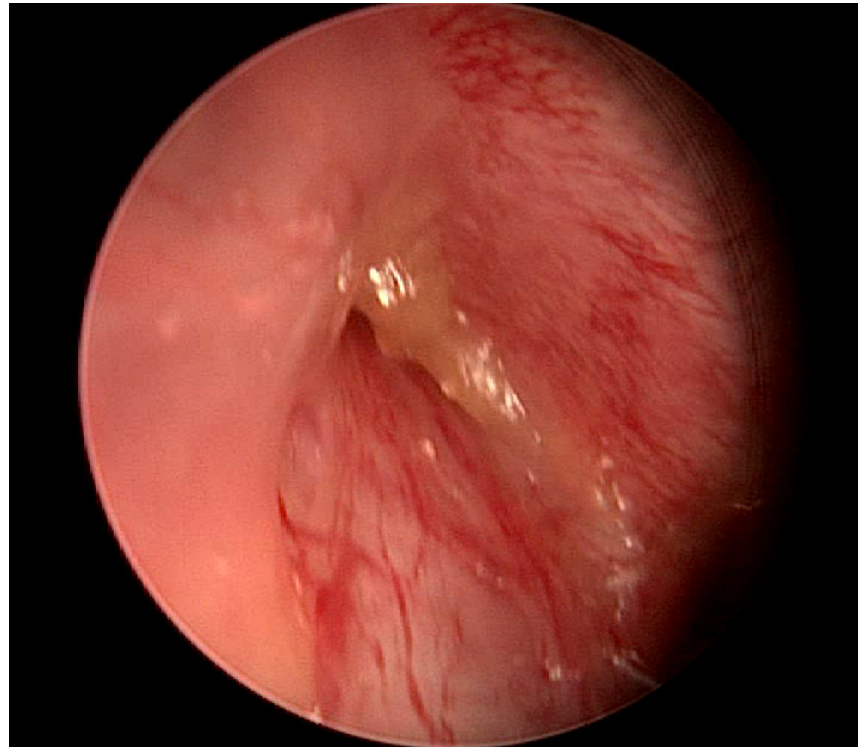
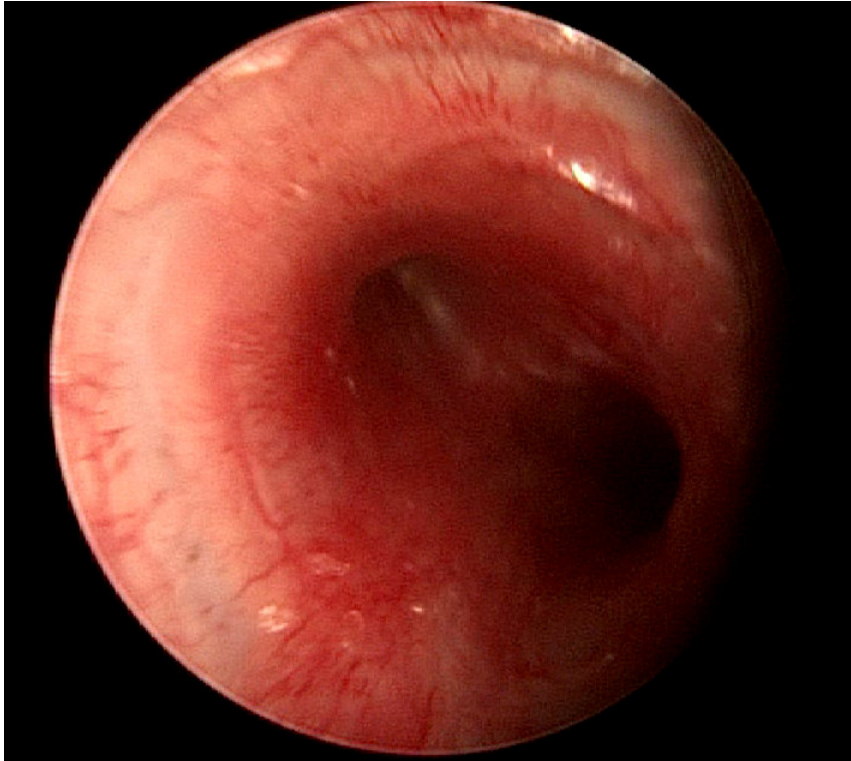

Anomalous left coronary artery



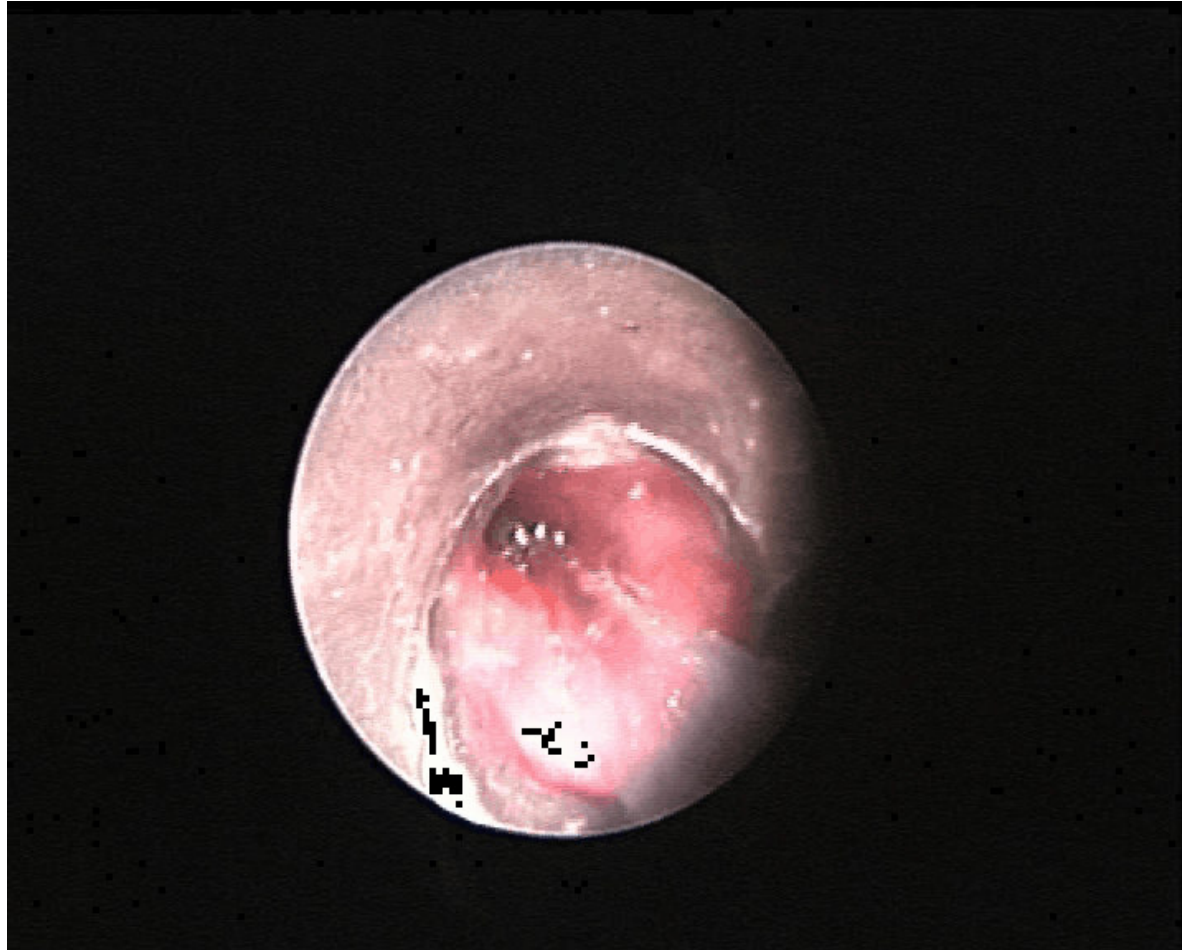


BRONCOSCOPIA





Posizionamento stent (Jostent 17 x 6/12)




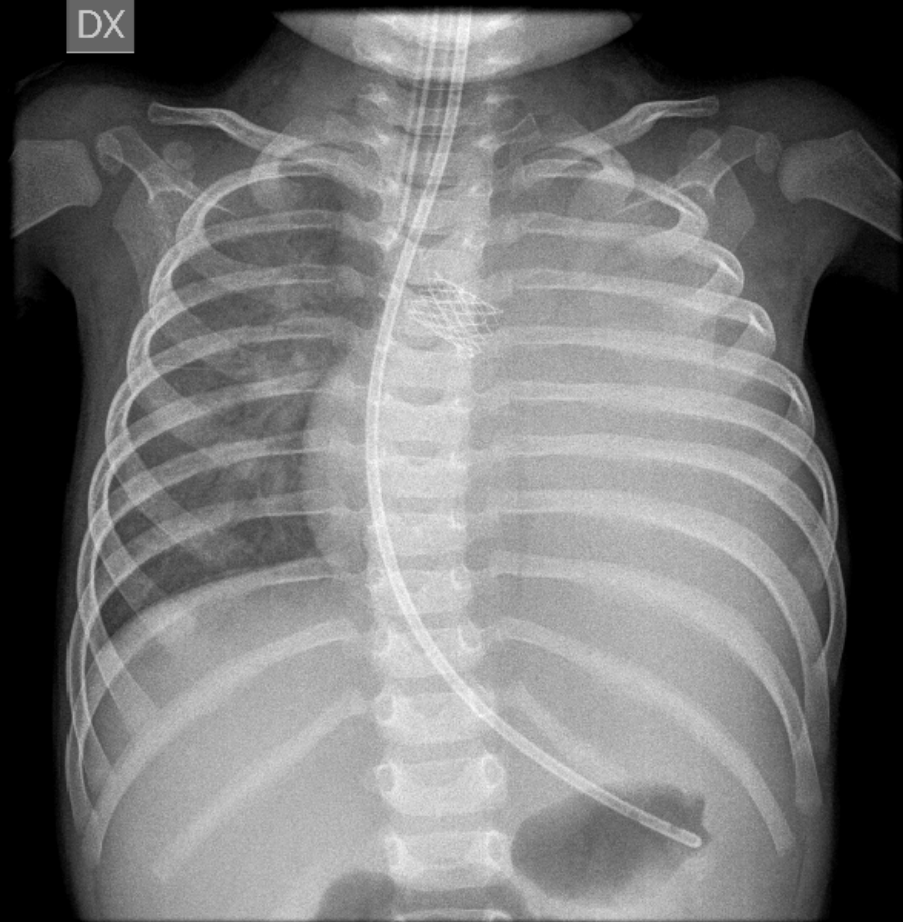
Name: LUCHI GIULIA
ID: ME2057288
DoB: 29/04/2010
Date: 23/02/2011
Time: 0.20.14
No.: 1
k: 0.33

H

Inst: A. O. U. MEYER
Model: DX-S

1

DX



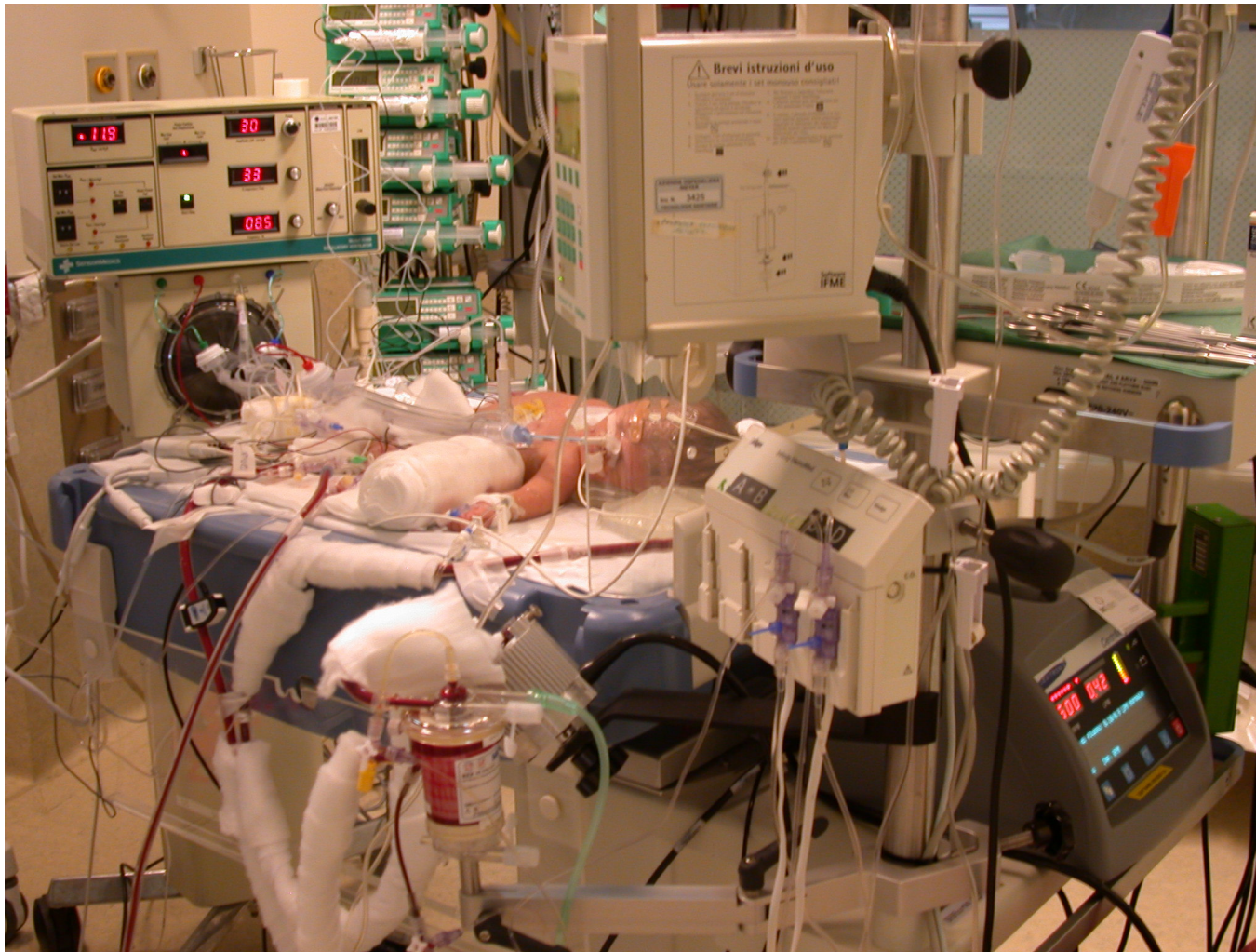
W : 04096
C : 02048

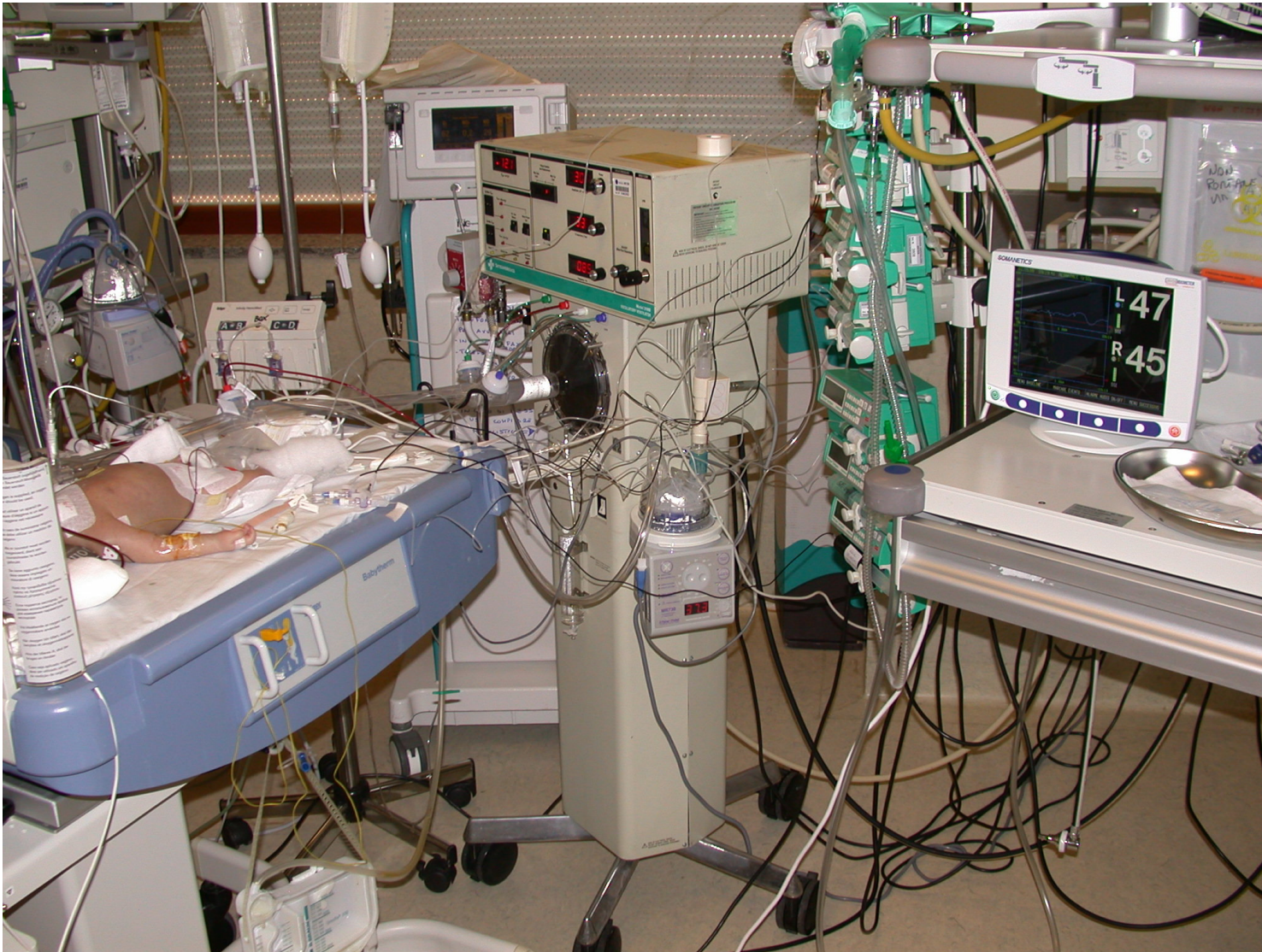

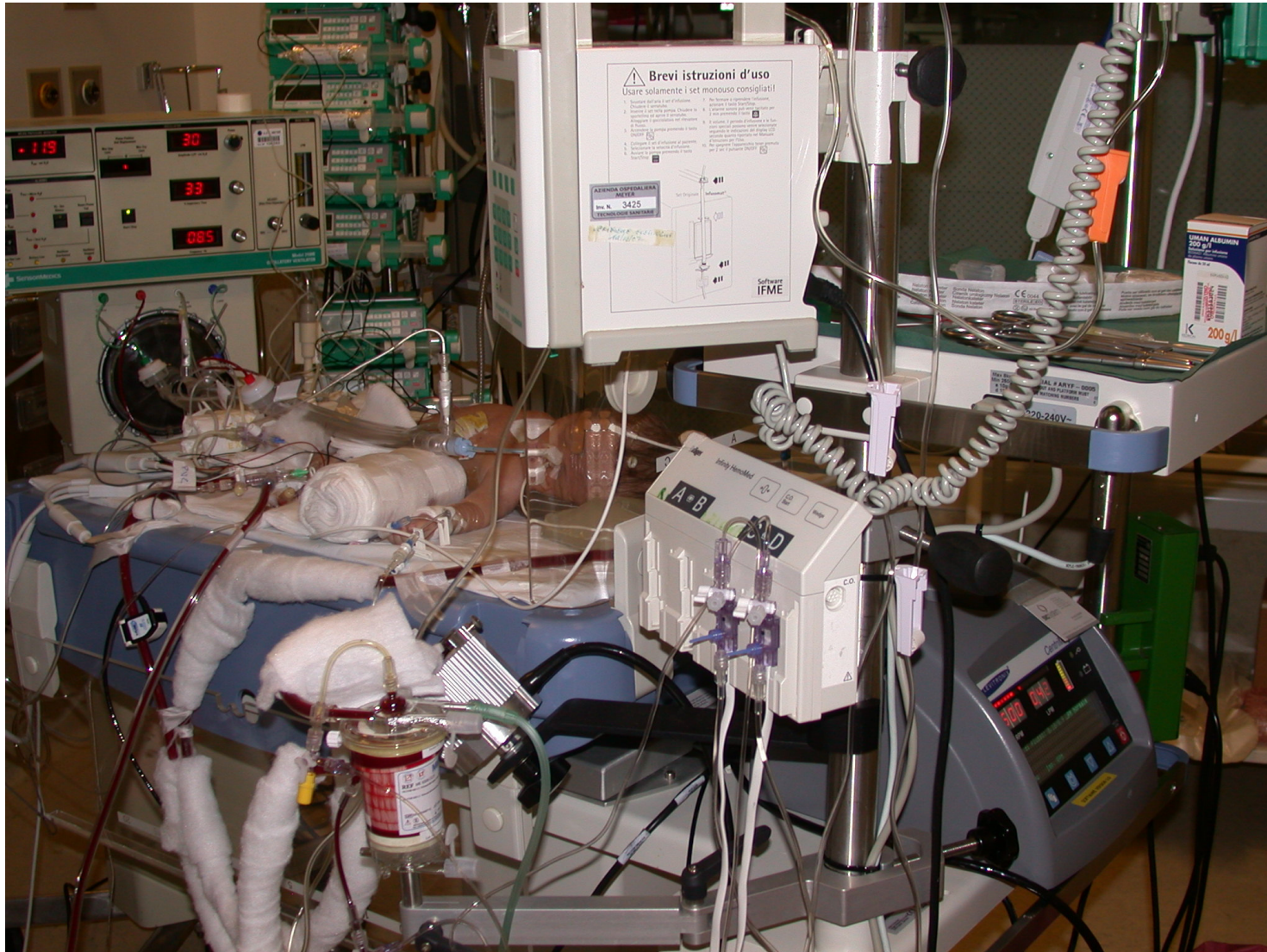
INTERVENTO CCH IN CEC



ASSISTENZA VENTRICOLARE SINISTRA







Name: LUCHI GIULIA
ID: ME2057288
DoB: 29/04/2010
Date: 23/02/2011
Time: 21.49.30
No.: 1
k 0.33

H

Inst: A. O. U. MEYER
Model: DX-S

1

DX

R

L

W : 04096
C : 02048

F

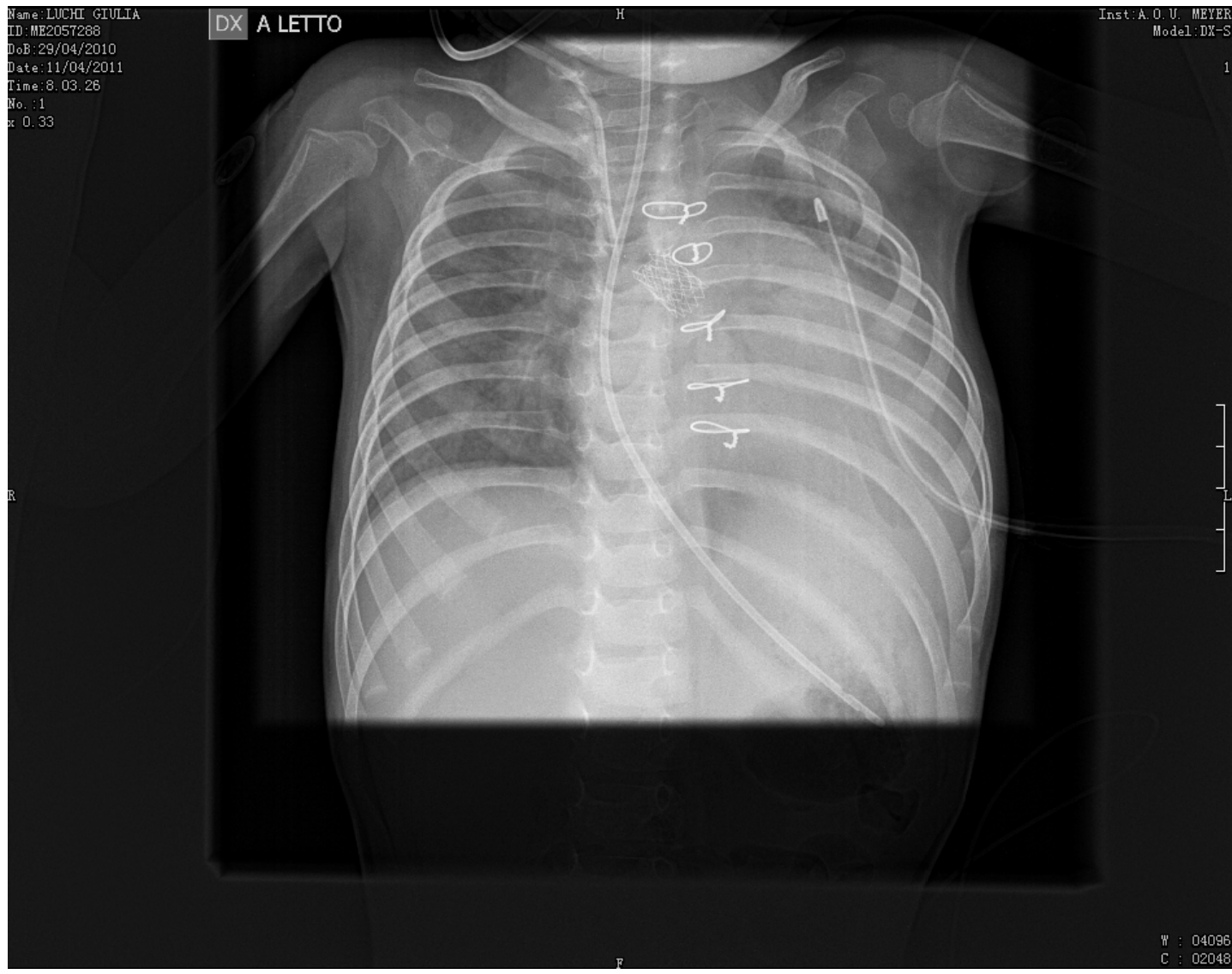


Name: LUCHI GIULIA
ID: ME2057288
DoB: 29/04/2010
Date: 11/04/2011
Time: 8.03.26
No.: 1
Ex: 0.33

DX A LETTO

Inst: A. O. U. MEYER
Model: DX-S

1



W : 04096
C : 02048

